



PATIENT

Jazzy Small

SPECIES

Feline

BREED

DLH

SEX

Female Spayed

AGE

2 years

WEIGHT

11lbs

INTERPRETED BY

Maggie Machen Lamy,
DVM, DACVIM
(Cardiology)

IMAGING PERFORMED BY

Tiffany Brady, DVM

HOSPITAL NAME

Shiloh Veterinary
Hospital

REFERRING VET

Dr. Brady

INVOICE

45986

DATE

12/3/25

PRESENTING CLINICAL SIGNS

History: Grade 4/6 heart murmur. Asymptomatic. Sedated with Torb and Dexdomitor.

ECHOCARDIOGRAM FINDINGS

Limited 2D, m-mode and doppler imaging is available. The left ventricular wall is normal in dimension. There is a mildly hyperechoic endocardium consistent with fibrosis. The papillary muscles are mildly hyperechoic. The left atrium is normal in size. The right atrium is normal in size. The right ventricle appears normal. Blood flow through the RVOT is decreased. LVOT velocity is not assessed; however, systolic anterior motion is seen on 2D imaging. No pleural or pericardial effusion seen. No obvious cardiac tumors.

CARDIAC CHART

| FELINE CARDIAC PARAMETERS | BODY WEIGHT (kg) | HR (BPM) | IVSd (cm) (Moise, Pipers) | LVIDd (cm) (Moise, Pipers) | LVWd (cm) (Moise, Pipers) | FS (%) | EF (%) |
|---------------------------|------------------|---------------------------------|--|----------------------------|---------------------------|-------------|--------|
| NORMAL PARAMETER | ----- | 150-240 | 0.35-0.55 | <2 (mean 1.5) | 3.5-0.55 | 35-67 | 80-100 |
| PATIENT | 5.0 | NM | 0.49 | 1.3 | 0.49 | 50 | 86 |
| FELINE CARDIAC PARAMETERS | LA/AO (Boon) | LA/AO HEART BASE (Swe) (Abbott) | LA 2D short axis Base view (cm) (Abbott) | LVOT VEL (m/s) | RVOT VEL (m/s) | E max (m/s) | |
| NORMAL | <1.5 | <1.3 | <1.2 | <1.6 | <1.3 | <0.9 | |
| PATIENT | NM | 1.2 | 1.1 | NM | 0.5 | NM | |

**Note: All measurements based upon multi-modal images and methods. An average value is reported.*
Adapted from June Boon, Veterinary Echocardiography, 1998
Abbott J & MacLean H JVIM 2006;20: 111-119, Moise et al. Am J Vet Res 47:1476, 1986. Pipers et al. Am J Vet Res 40:882, 1979.

INTERPRETATION OF THE FINDINGS & FURTHER RECOMMENDATIONS

The only abnormality identified is systolic anterior of the mitral valve likely causing an LVOT obstruction. The diagnosis is suspected, as color flow is inaccurate and spectral doppler not assessed. Despite this, the LV wall thickness and LA dimension are normal suggesting little significance at this time. No additional issues are seen. It is important to note that small abnormalities may have been missed without a complete study.

Given these findings, no medications are indicated. Should the LVOT obstruction worsen, and hypertrophy develop, Atenolol may be recommended in the future.

Prognosis is guarded. No correlation to current clinical signs is suspected.

Anesthetic risk is considered mild. Drugs that stimulate heart rate should be avoided unless clinically necessary (glycopyrrolate, atropine).

Monitor for any development of clinical signs, including labored breathing or signs of a blood clot (paralysis, neurologic change). Prognosis is guarded prior to assessing for progression.

A recheck echocardiogram is recommended in 1 year to screen for any evidence of progression.



PATIENT

Jazzy Small

SPECIES

Feline

BREED

DLH

SEX

Female Spayed

AGE

2 years

WEIGHT

11lbs

INTERPRETED BY

Maggie Machen Lamy,
DVM, DACVIM
(Cardiology)

IMAGING PERFORMED BY

Tiffany Brady, DVM

HOSPITAL NAME

Shiloh Veterinary
Hospital

REFERRING VET

Dr. Brady

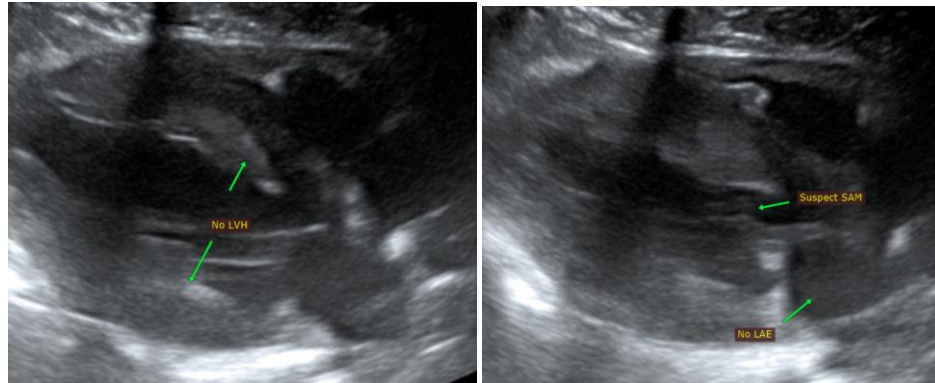
INVOICE

45986

DATE

12/3/25

IMAGES



The information and recommendations provided are based on the images presented by the referring veterinarian. No evaluation can be communicated regarding pathology that was not visible in the image/video clips provided.

Thank you for this referral. This report was generated using transcription software, and minor dictation errors may be present. If the clinical or image interpretation does not parallel your findings or if I can be of any further assistance, please contact me.

Maggie Machen Lamy, DVM
Diplomate of the American College of Veterinary Internal Medicine (Cardiology)
info@sonopath.com